



PRESENTING CLINICAL SIGNS

History: Weight loss and intermittent GI signs. Enlarged prostate. ECG showed left axis deviation and occasional VPCs. Normal thoracic radiographs. BNP 2163.

DATE

1/6/22

ECHOCARDIOGRAPHIC FINDINGS

2D, M-mode, and Doppler study.

PERFORMED BY:

Jenna Walsh, CVT

INTERPRETED BY

Keith Blass, DVM,
MS, DACVIM
(Cardiology)

Left atrial size is normal. The mitral valve leaflets are very mildly thickened, and a very mild jet of mitral regurgitation is present. Left ventricular dimensions are normal. Left ventricular systolic function is normal. The aorta and aortic valve appear normal, though trace aortic insufficiency is present. There is mild right atrial and right ventricular dilation. The tricuspid valve leaflets are mildly thickened, and a mild jet of tricuspid regurgitation is present. TR velocity does not suggest the presence of pulmonary hypertension. The pulmonary artery and pulmonic valve are normal. No shunting lesions are visualized. No pericardial effusion or cardiac masses are seen.

PATIENT

Kirby Johnson

LA - 40.5 mm
LVIDd - 46.3 mm
LVIDs - 31.4 mm
FS - 32%
RA - 31.2 mm
LVOT - 1.48 m/s
RVOT - 1.03 m/s
TR - 2.49 m/s

SPECIES

Canine

ASSESSMENT/RECOMMENDATIONS

Degenerative mitral and tricuspid valve disease

BREED

Bouvier

This examination demonstrates mild regurgitation of blood across Kirby's mitral and tricuspid valves resulting from degenerative valve disease. The hemodynamic effects of each of the regurgitations also appear to be mild, as Kirby does not have secondary dilation of any of his cardiac chambers. As such, Kirby's valvular diseases appear to be well-compensated, and his current risk for the development of clinical signs secondary to them appears to be low.

SEX

No therapy is recommended at this stage of Kirby's valvular diseases.

MI

A recheck echocardiogram is recommended in 6 months to monitor for disease progression.

AGE

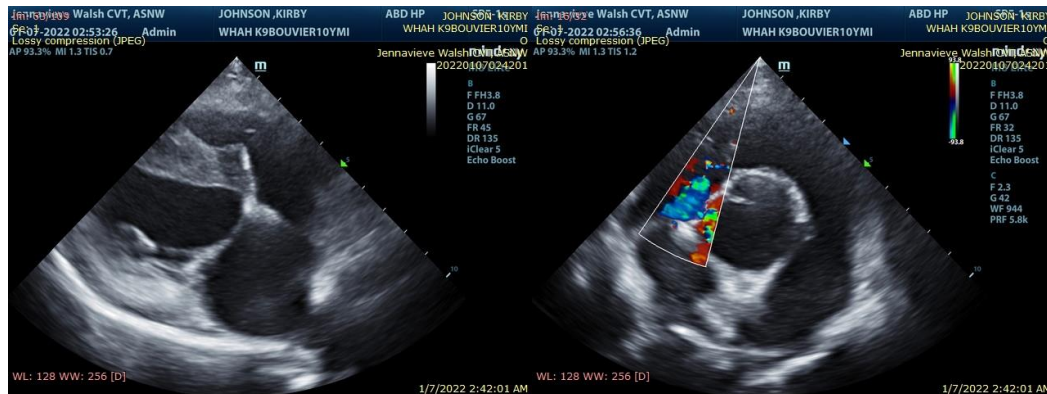
10 y

WEIGHT

61 lb

HOSPITAL NAME

West Hills AH



REFERRING VET

Dr. Remcho



DATE

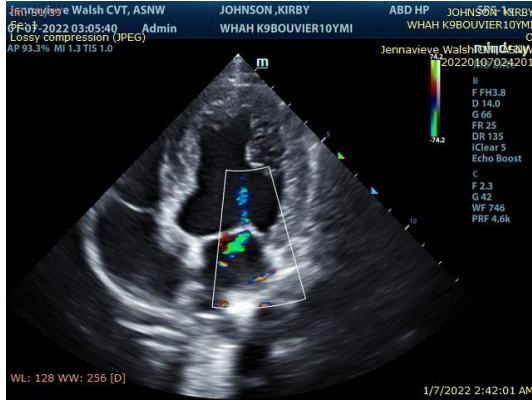
1/6/22

PERFORMED BY:

Jenna Walsh, CVT

INTERPRETED BY

Keith Blass, DVM,
MS, DACVIM
(Cardiology)



The information and recommendations provided are based on the images presented by the referring veterinarian. No evaluation can be communicated regarding pathology that was not visible in the image/video clips provided.

Thank you for this referral. If the clinical or image interpretation does not parallel your findings or if I can be of any further assistance please contact me.

PATIENT

Kirby Johnson

Keith Blass, DVM, MS, DACVIM (Cardiology)
KeithBlass@gmail.com
631-804-5754

SPECIES

Canine

BREED

Bouvier

SEX

MI

AGE

10 y

WEIGHT

61 lb

HOSPITAL NAME

West Hills AH

REFERRING VET

Dr. Remcho